

Computed tomography angiography spot sign predicts intraprocedural aneurysm rupture in subarachnoid hemorrhage

Jan-Karl Burkhardt¹ · Marian Christoph Neidert¹ · Martin Nikolaus Stienen^{2,3} · Daniel Schöni⁴ · Christian Fung⁴ · Michel Roethlisberger⁵ · Marco Vincenzo Corniola³ · David Bervini⁴ · Rodolfo Maduri⁶ · Daniele Valsecchi⁷ · Sina Tok¹ · Bawarjan Schatlo⁸ · Philippe Bijlenga³ · Karl Schaller³ · Oliver Bozinov¹ · Luca Regli¹ · on behalf of the Swiss SOS study group

Received: 9 November 2016 / Accepted: 28 December 2016 / Published online: 27 January 2017
© Springer-Verlag Wien 2017

Abstract

Introduction To analyze whether the computed tomography angiography (CTA) spot sign predicts the intraprocedural rupture rate and outcome in patients with aneurysmal subarachnoid hemorrhage (aSAH).

Methods From a prospective nationwide multicenter registry database, 1023 patients with aneurysmal subarachnoid hemorrhage (aSAH) were analyzed retrospectively. Descriptive statistics and logistic regression analysis were used to compare spot sign-positive and -negative patients with aneurysmal intracere-

bral hemorrhage (aICH) for baseline characteristics, aneurysmal and ICH imaging characteristics, treatment and admission status as well as outcome at discharge and 1-year follow-up (1YFU) using the modified Rankin Scale (mRS).

Results A total of 218 out of 1023 aSAH patients (21%) presented with aICH including 23/218 (11%) patients with spot sign. Baseline characteristics were comparable between spot sign-positive and -negative patients. There was a higher clip-to-coil ratio in patients with than without aICH (both spot sign positive and negative). Median aICH volume was significantly higher in the spot sign-positive group (50 ml, 13–223 ml) than in the spot sign-negative group (18 ml, 1–416; $p < 0.0001$). Patients with a spot sign-positive aICH thus were three times as likely as those with spot sign-negative aICH to show an intraoperative aneurysm rupture [odds ratio (OR) 3.04, 95% confidence interval (CI) 1.04–8.92, $p = 0.046$]. Spot sign-positive aICH patients showed a significantly worse mRS at discharge ($p = 0.039$) than patients with spot sign-negative aICH (median mRS 5 vs. 4). Logistic regression analysis showed that the spot sign was an aICH volume-dependent predictor for outcome. Both spot sign-positive and -negative aICH patients showed comparable rates of hospital death, death at 1YFU and mRS at 1YFU.

Conclusion In this multicenter data analysis, patients with spot sign-positive aICH showed higher aICH volumes and a higher rate of intraprocedural aneurysm rupture, but comparable long-term outcome to spot sign-negative aICH patients.

Keywords Aneurysmal subarachnoid hemorrhage (aSAH) · Computed tomography angiography (CTA) spot sign · Intracerebral hemorrhage (ICH) · Intraprocedural aneurysm rupture

✉ Jan-Karl Burkhardt
Jan-karl.Burkhardt@usz.ch

on behalf of the Swiss SOS study group

¹ Department of Neurosurgery, University Hospital Zurich, University of Zurich, Zurich, Switzerland

² Department of Neurosurgery, Kantonsspital St. Gallen, St. Gallen, Switzerland

³ Department of Neurosurgery, Hospitaux Universitaires de Geneve (HUG), Geneva, Switzerland

⁴ Department of Neurosurgery, Inselspital Bern, Bern, Switzerland

⁵ Department of Neurosurgery, University Clinic Basel, Basel, Switzerland

⁶ Department of Neurosurgery, Centre Hospitalier Universitaire Vaudois (CHUV), Lausanne, Switzerland

⁷ Department of Neurosurgery, Ospedale Regionale di Lugano, Lugano, Switzerland

⁸ Department of Neurosurgery, University Hospital Göttingen, Göttingen, Germany

Introduction

Aneurysmal subarachnoid hemorrhage (aSAH) is responsible for approximately 5% of all new strokes and leads to a mortality of approximately 51% with one third of survivors needing lifelong care [15]. Especially patients with aSAH and intracerebral hemorrhage (ICH) show worse outcome than patients without ICH [9, 12, 13]. In Switzerland, a nationwide registry was implemented for aSAH patients to allow for better understanding of the disease, its treatment and outcomes [14].

The computed tomography angiography (CTA) spot sign was first described in primary ICH and is defined as contrast extravasate within the ICH [7, 8, 17]. In primary ICH, the spot sign is a predictor for ICH volume increase and patient outcome [7]. The significance of the spot sign in stratifying patients with aneurysmal ICH (aICH) and in predicting their outcome has raised interest only recently [1, 4]. Browsers et al. showed that spot sign-positive patients with aICH had a comparable short-term outcome as spot sign-negative patients in consecutive series from two different centers [1]. In a single center study, we recently showed that aICH spot sign-positive patients had a higher risk of intraoperative aneurysm rupture during microsurgical clipping than patients without the spot sign in the preoperative CTA [4]. Since only few reports investigating the spot sign in aICH are available [1, 6], the aim of this study was to further analyze the significance of the spot sign for the treatment course and outcome of patients with aICH in a nationwide multicenter aSAH registry [14].

Methods

Inclusion criteria

All anonymous patient data from 2008–2013 were obtained from the nationwide multicenter registry database [IRB no. 11-233R (NAC 11-085R)] and approved by the local Zurich ethics committee (54-2015). At the time of analysis, 1570 consecutive patients treated for aSAH were included in the registry [14]. All patients with a complete data set including a CT/CTA at admission in order to analyze the ICH/spot sign ($n = 1023$) were included for this data analysis. Data regarding the presence of the spot sign were added retrospectively to the prospective registry. Anonymous patient data from the following neurosurgical centers were analyzed: Basel, Bern, Geneva, Lausanne, Lugano, St. Gallen and Zurich. Four patients with the spot sign had been previously reported in the single-center analysis [4].

Clinical patient data

Age, gender, body mass index (BMI), tobacco use, anticoagulation/antiplatelet use as well as date and duration

of admission, aSAH ictus, treatment modality (coiling, clipping, none), clinical admission scores including GCS and WFNS scores and outcome at discharge and 1-year follow-up (1YFU) using the modified Rankin Scale (mRS) were used for analysis.

Radiological data

Each participating center collected radiographic data for this study based on CT/CTA and conventional angiography to measure aneurysmal and ICH characteristics including the presence of ICH, IVH and the spot sign, size of the ICH before and after treatment, localization of the ICH and aneurysm, and the size and number of aneurysms. Data extraction was performed at each center by an experienced neurosurgeon.

Size of the ICH was calculated based on the following formula: $(X/2 * Y/2 * Z/2) * (4/3) * \text{Pi}$ with X = anterior to posterior ICH extension in axial CT, Y = lateral to medial ICH extension in axial CT and Z = superior to inferior ICH extension on coronal CT. Intraprocedural aneurysm rupture was defined as any aneurysm rupture event reported in the surgical report during surgical clipping or endovascular coiling. No subgrouping such as minor or major rupture leaks was used for analysis.

The spot sign was defined as previously described including all of the following four criteria: (1) ≥ 1 focus of contrast pooling within the ICH; (2) spot sign with an attenuation ≥ 120 Hounsfield units; (3) spot sign discontinuous from normal/abnormal vasculature adjacent to the ICH; (4) of any size and morphology [1, 6].

Statistical testing

Statistical analysis was performed using SPSS 20 (IBM, Chicago, IL, USA), and figures were generated using GraphPad Prism (GraphPad Software, San Diego, CA, USA). Continuous variables are presented as mean with standard error of the mean. Comparisons between groups were performed using the Mann Whitney U test for continuous parameters and the chi-square test or Fisher's exact test for categorical parameters and logistic regression analysis to calculate the odds ratio. Statistical significance was established at the alpha level of $p = 0.05$.

Results

Overall results

In total 218 out of 1023 patients (21%) presented with ICH in addition to aSAH. Of these patients 23 (11%) showed a spot sign compared to 195 (89%) patients without a spot sign on

Table 1 Patient characteristics

	aICH	Spot sign-positive aICH	Spot sign-negative aICH	P value
Age (mean, SD)	57 (12)	57 (13)	57 (12)	0.79
Sex (female)	145 (67%)	13 (57%)	127 (65%)	0.28
Tobacco use	42 (40%)	4 (31%)	37 (19%)	0.72
BMI (mean, SD)	25 (5)	22 (3)	25 (5)	0.05
Antiplatelet medication	28 (13%)	4 (17%)	24 (12%)	0.48
Oral anticoagulation	6 (3%)	2 (9%)	4 (2%)	0.48
Patient number	n = 218 (100%)	n = 23 (11%)	n = 195 (89%)	

*p-value is calculated between spot sign-positive and -negative patients; aICH, aneurysmal intracerebral hemorrhage; SD, standard deviation; BMI, body mass index in kg/m²

CTA. Nineteen patients had one, one patient had two and three patients had three spot signs within the ICH. Baseline characteristics including age, gender, tobacco use, BMI and the use of antiplatelet medication or oral anticoagulation were not statistically significant between the spot sign-positive and -negative groups (Table 1).

Radiographic results

Intraventricular blood extension, presence of multiple aneurysms, aneurysm location and aneurysm diameter were comparable between the spot sign-positive and -negative groups ($p > 0.05$). ICH volume before treatment was significantly

higher in the spot sign-positive than in the spot sign-negative group ($p < 0.0001$) (Fig. 1a, Table 2). ICH volume after surgical clipping with hematoma evacuation as well as hematoma volume reduction after surgery was comparable between spot sign-positive and -negative patients, respectively ($p > 0.05$; Fig. 1b-c). Initial hematoma volume was higher in the clipping and no treatment group compared to the coiling group (Fig. 1d)

Treatment and intraprocedural aneurysm rupture

Among the patients with aICH, most of the aneurysms were clipped 116/218 (53%) compared to coiled (65/218, 30%),

Fig. 1 Box plots depicting (a) the initial hematoma volume in patients with the spot sign ($n = 23$) versus patients without the spot sign ($n = 194$), (b) the hematoma volume and the hematoma volume reduction (c) after clipping in patients with the spot sign ($n = 15$) versus patients without the spot sign ($n = 101$), and (d) the initial hematoma volumes in patient undergoing clipping ($n = 116$), coiling ($n = 65$) or no treatment ($n = 37$). The boxes show the median as well as the interquartile range; whiskers show the 10th percentile (lower) and the 90th percentile (upper) with outliers depicted as dots

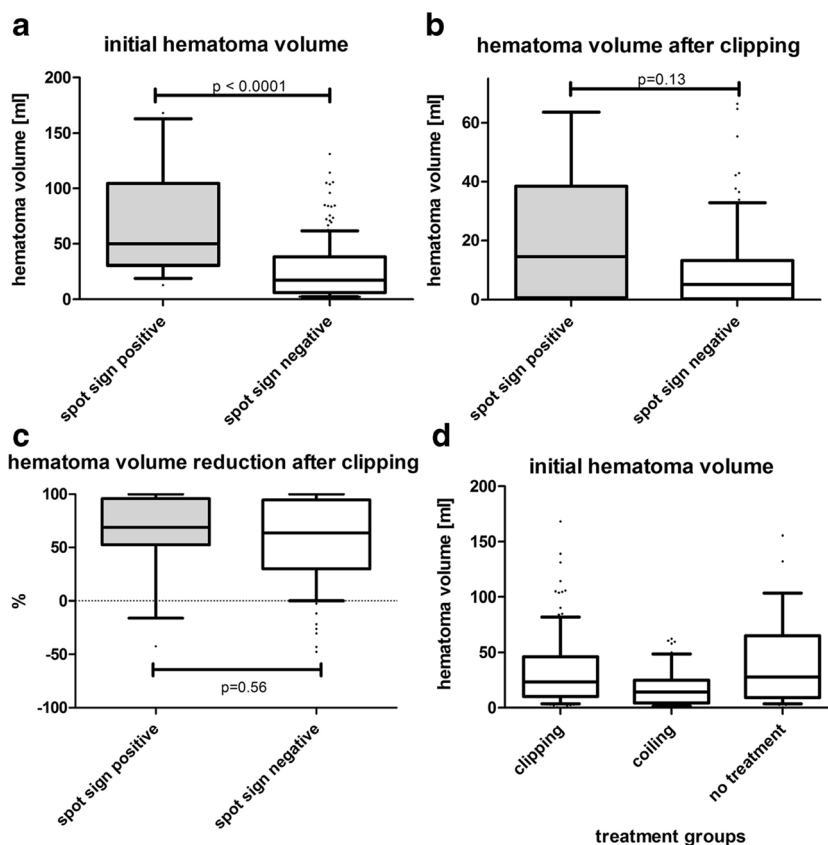


Table 2 Radiographic results

	aICH	Spot sign-positive aICH	Spot sign-negative aICH	P value*
Intraventricular hemorrhage	92 (67%)	10 (43%)	79 (41%)	0.34
Multiple aneurysms	82 (38%)	6 (26%)	74 (38%)	0.89
Aneurysm location (anterior circulation)	126 (61%)	13 (65%)	108 (55%)	0.39
Aneurysm diameter, mm (median, range)	7 (2–39)	7 (2–25)	7 (2–39)	0.79
ICH volume baseline, ml (median, range)	20 (1–416)	50 (13–223)	17 (1–416)	<0.0001
Patient number	n = 218 (100%)	n = 23 (11%)	n = 195 (89%)	

*p-value is calculated between spot sign-positive and negative patients; aICH, aneurysmal intracerebral hemorrhage

and 37 patients had no aneurysm treatment (37/218, 17%); however, these differences were not statistically significant ($p=0.51$) (Fig. 2, Table 3). Out of the 181 patients with aICH and aneurysm treatment, 18 (18/181, 10%) had a spot sign and 163 (163/181, 90%) had no spot sign on the CTA. An intraoperative aneurysm rupture occurred in 29 patients (29/181, 16%); 6 had a positive and 23 a negative spot sign on CTA. Intraoperative aneurysm rupture occurred in 6 out of 18 patients (33%) with a spot sign-positive aICH and 23 out of 163 patients (14%) with a spot sign-negative aICH ($p=0.03$). Patients with a spot sign-positive aICH thus were three times as likely as those with spot-sign-negative aICH to show an intraoperative aneurysm rupture [odds ratio (OR) 3.04, 95% confidence interval (CI) 1.04–8.92, $p=0.046$].

Most of the spot sign-positive patients with an intraoperative rupture event were in the clipping group (5/6 patients, 83%), and a comparable distribution between clipping and coiling was found in the spot sign-negative group (12/23 patients, 52% clipping group).

Outcome

Both in-hospital death (HD) and death at 1-year follow-up (1YD) were significantly higher in patients with aICH compared to patients without ICH (Table 4). Patients with aICH were 2.8 times as likely as patients without aICH to be dead at discharge (OR 2.80, 95% CI 1.99–3.92, $p<0.001$) and to be dead at 1YFU (OR 2.84, 95% CI 2.03–3.97, $p<0.001$). Outcomes measured by dichotomized mRS (0–2 vs. 3–6) at discharge and at 1YFU were significantly worse in patients with aICH (median mRS 4) compared to patients without aICH (median mRS 2; Fig. 3).

Although spot sign-positive aICH patients showed a significantly worse outcome at discharge than patients with a negative spot sign (median mRS 5 vs. 4; $p=0.039$, Fig. 3a), there were no differences between the groups for HD [11/23 (48%) vs. 59/195 (31%); $p=0.75$], 1YD [11/23 (48%) vs. 62/195 (33%); $p=0.64$] and neurological outcome at 1YFU

($p=0.37$) (Fig. 3b). Length of hospital stay (23 vs. 24 days, $p=0.16$) and the incidence of delayed ischemic neurological deficits (both 35%, $p=0.89$) were comparable in both spot sign-positive and -negative patients.

Discussion

In this study, we analyze the frequency and implications of the CTA spot sign in aSAH patients from a nationwide multicenter registry database and confirmed that only a small subgroup of aSAH patients (11%) is diagnosed with a CTA spot sign. This is in concordance with a recent study demonstrating that the spot sign is less common in aSAH patients than in primary ICH patients (14 vs. 30%) [1]. Also the proportion of 21% of associated aICH among all aSAH patients is in concordance with the literature [11, 16].

Radiographic results

The pretreatment aICH volume was significantly higher in spot sign-positive than -negative patients and confirms the results as previously published by Brouwers et al. [1]. This result is not surprising since previous studies showed

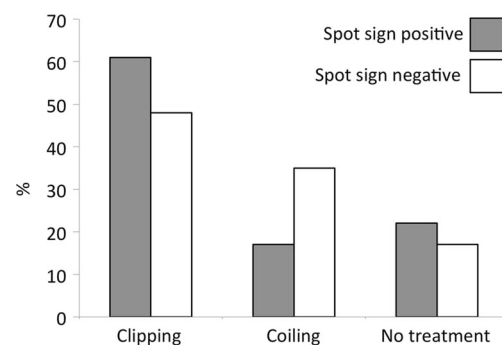


Fig. 2 The frequency of the treatment modalities for aSAH patients with aICH is shown for the spot sign group (gray bars) and the group without a spot sign (white bars) separately

Table 3 Aneurysm treatment

	No aICH	aICH	Spot sign-positive aICH	Spot sign-negative aICH
Clipping	274 (34%)	116 (53%)	14/23 (61%)	102/195 (52%)
Coiling	453 (56%)	65 (30%)	4/23 (17%)	61/195 (31%)
No treatment	78 (10%)	37 (17%)	5/23 (22%)	32/195 (17%)
Intraoperative aneurysm rupture	No data	29/181 (16%)	6/18 (33%)	23/163 (14%)

aICH, aneurysmal intracerebral hemorrhage

that the spot sign is a predictor for ICH progression in primary ICH [2, 3, 5]. Therefore, it is likely that also aSAH patients will have larger or progressive aICH volumes compared to spot sign-negative patients. Interestingly, hematoma volume reduction was comparable between the two groups after surgery.

Treatment and intraoperative aneurysm rupture

Most of the patients with aICH in this study were clipped (64%) rather than coiled (36%). This finding is not surprising since the indication for microsurgical intervention is made in patients with aICH and aSAH to evacuate the aICH and decrease the space-occupying effect, which is not possible with endovascular intervention. Since this is not a randomized study, there is a selection bias, and more aICH patients were treated with clipping and hematoma evacuation than with coiling alone. Also clipped patients had a larger pretreatment aICH volume than patients with aneurysm coiling.

With regards to intraoperative aneurysm rupture, the data show that patients with spot sign-positive aICH have a statistically higher risk of intraoperative aneurysm rupture than spot sign-negative patients (OR 3.04, 95% CI 1.04–8.92, $p=0.046$). These results confirmed our previously published results from a single center showing that patients with spot sign-positive aSAH have a higher risk of intraoperative aneurysm rupture during clipping [4]. The clinical implication of this finding is important:

neurovascular surgeons aiming to occlude a ruptured aneurysm in a patient with aICH should be aware of a higher risk of rebleeding. Whenever possible, particularly careful dissection of the neurovascular anatomy is recommended. Although the CTA spot sign is an indirect sign for active bleeding in primary ICH and therefore a higher risk for intraoperative aneurysm rupture can be assumed, the spot sign in aICH patients is not always in direct contact with the aneurysm [1].

The pathophysiological mechanism of the spot sign in aSAH is not completely understood yet, and further research is needed. Based on research on primary ICH patients, one can assume that also spot sign-positive aSAH patients have a more fragile vasculature than spot sign-negative SAH patients, therefore leading to rupture of the small fragile vasculature around the ICH as well as the large fragile vessel walls, including the aneurysm, and therefore a higher likelihood of vessel rupture during aneurysm treatment. In this theory, the spot sign would be a radiological marker indicating vessel fragility.

An alternative theory is based on the dynamics of the initial rupture. Patients with a more severe initial rupture (i.e., a larger vessel wall defect in the aneurysm dome or higher systemic blood pressure) suffer from larger volume bleedings and especially more rapid hematoma enlargement. In this setting, the rapid bleeding dynamics lead to elevated shear stress, which in turn causes more damage to the neighboring tissue around the aICH including the rupture of small vessels causing a spot sign.

Table 4 Patient outcome

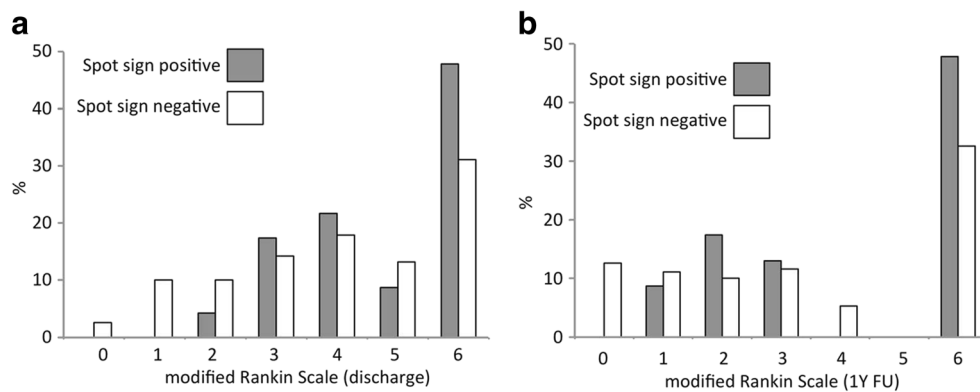
	No aICH	aICH	P value ¹	Spot sign-positive aICH	Spot sign-negative aICH	P value ²
Length of hospital stay in days	22 (18)	23 (16)	$p=0.39$	23 (15)	24(16)	$p=0.16$
In-hospital death	125 (16%)	74 (34%)	<0.0001	11 (48%)	59 (31%)	$p=0.75$
1-year FU death	130 (16%)	77 (35%)	<0.0001	11 (48%)	62 (33%)	$p=0.64$
DIND	241 (30%)	76 (35%)	$p=0.38$	8 (35%)	66 (35%)	$p=0.89$
Patient number	n = 805	n = 218		n = 23 (11%)	n = 195 (89%)	

The neurological outcome at discharge and 1-year follow-up (FU) is illustrated in Fig. 3

1: p-value is calculated between no-aICH patients and aICH patients

2: p-value is calculated between spot sign-positive and -negative aICH patients; aICH, aneurysmal intracerebral hemorrhage; DIND, delayed ischemic neurological deficit

Fig. 3 Clinical outcome measured as modified ranking scale is shown for aICH patients with a spot sign (gray bars) and without a spot sign (white bars) at discharge (a) and at 1-year follow-up (b)



Outcome

In our study population, outcome was significantly dependent on the presence of aICH, and patients with an aICH had an almost two-fold higher likelihood to be dead at discharge and at the 1YFU. They had a worse mRS at discharge and at the 1YFU. These results support the findings in the literature, which show that aICH is a predictor for outcome in aSAH [10, 11, 16].

With regards to the spot sign, we did not find statistically significant differences in terms of the death rate and 1-year clinical outcome compared to spot sign-negative patients. Brouwers et al. had similar findings with no differences in death rate and 30-day clinical outcome between spot sign-positive and -negative patients [1]. In our study we could confirm this comparable outcome even at the 1YFU. Although there was a difference in the mRS at discharge, this effect was not statistically significant at the 1YFU.

Both length of hospital stay and DIND were comparable between patients with and without aICH as well as between spot sign-positive and -negative aICH patients. Although larger cisternal aSAH extension is associated with a higher probability of DIND [18], this was not the case for patients with aICH extension. Since DIND usually prolongs the hospital stay, all groups had a comparable hospital stay.

Study limitations

Although the data analysis is based on a multicenter nationwide registry, imaging data collection including volume measurement and spot sign was performed retrospectively by each treating center. There was no information on the time span between ictus and CTA, which might influence the spot sign incidence. However, since this is a study from a small country with short commutes to the main national aSAH treating centers enrolled in this study, we believe that the time span between ictus and CTA is short and comparable among all centers. The information on intraprocedural rupture was based on the treatment report. There was also no randomization to treatment groups especially in patients with aICH (clipping,

coiling), and therefore selection bias applies. Patients with the spot sign showed larger aICH volumes, and these patients were more likely clipped than coiled. Thus, this is a collinear confounder with aICH volume being the more likely cause for surgical clipping than the presence of a spot sign. In addition, the analysis of post-clipping hematoma volumes is limited by different surgical strategies in the setting of aSAH accompanied by aICH. There is no consensus on the questions of whether and to what extent intraparenchymal hematomas should be evacuated in this setting. Except for one center, all main national aSAH-treating centers took part in this study; therefore, this patient population is representative of the Swiss aSAH population.

Conclusion

In this multicenter data analysis, patients with CTA spot sign-positive aICH showed a higher baseline aICH volume, a two-times higher intraprocedural aneurysm rupture and a worse dichotomized mRS at discharge compared to spot sign-negative ICH patients. At 1-year follow-up, the clinical outcome and death rate were comparable between the two groups.

Compliance with ethical standards

Funding No funding was received for this research.

Conflict of Interest All authors certify that they have no affiliations with or involvement in any organization or entity with any financial interest (such as honoraria; educational grants; participation in speakers' bureaus; membership, employment, consultancies, stock ownership, or other equity interest; and expert testimony or patent-licensing arrangements), or non-financial interest (such as personal or professional relationships, affiliations, knowledge or beliefs) in the subject matter or materials discussed in this manuscript.

Ethical approval All procedures performed in studies involving human participants were in accordance with the ethical standards of the institutional and national research committee and with the 1964 Helsinki Declaration and its later amendments or comparable ethical standards. For this type of study formal consent is not required.

Appendix

Swiss SOS Study Group Members / Collaborators:

Ali-Reza Fathi, MD, Javier Fandino, MD, Serge Marbacher, MD, Donato D'Alonzo, MD, Hassen Kerkeni, MD, Jahuda Soleman, MD, Daniel Coluccia, MD, Carl Muroi, MD, Hiroki Danura, MD: *Department of Neurosurgery, Kantonsspital Aarau*; Nicole Schmid, PhD: *Neuropsychological Unit, Department of Neurology, Kantonsspital Aarau, Switzerland*; Daniel Zumofen, MD, Michel Röthlisberger, MD, Luigi Mariani, MD, Rahael Guzman, MD, PhD: *Department of Neurosurgery, Universitätsspital Basel*; Andreas U. Monsch, PhD, Stephan Bläsi, PhD: *Neuropsychological Unit, Department of Neurology, Universitätsspital Basel, Switzerland*; Christian Fung, MD, David Bervini, MD, Jürgen Beck, MD, Andreas Raabe, MD, Johannes Goldberg, MD, Daniel Schöni, MD: *Department of Neurosurgery, Inselspital Bern*; Jan Gralla, MD: *Department of Neuroradiology, Inselspital Bern*; Antoinette Zweifel-Zehnder, PhD, Klemens Gutbrod, MD, Rene Müri, PhD: *Neuropsychological Unit, Department of Neurology Inselspital Bern, Switzerland*; Rodolfo Maduri, MD, Roy Thomas Daniel, MD, Daniele Stamoni, MD, Mahmoud Messerer, MD, Marc Levivier, MD: *Department of Neurosurgery, Centre Hospitalier Universitaire Vaudois, Lausanne*; Valérie Beaud, PhD: *Neuropsychological Unit, Department of Neurology, Centre Hospitalier Universitaire Vaudois, Lausanne, Switzerland*; Daniele Valsecchi, MD, Marta Arrighi, MD, Alice Venier, MD, Michael Reinert, MD Dominique E. Kuhlen, MD, Thomas Robert, MD: *Department of Neurosurgery, Ente Ospedaliero Cantonale Lugano, Lugano*; Stefania Rossi, PhD, Leonardo Sacco, MD: *Neuropsychological Unit, Department of Neurology, Ente Ospedaliero Cantonale Lugano, Lugano, Switzerland*; Philippe Bijlenga, MD, PhD, Marco Corniola, MD, Karl Schaller, MD: *Department of Neurosurgery, Hôpitaux Universitaires de Genève, Geneva*; Christian Chicherio, PhD: *Neuropsychological Unit, Department of Neurology, Hôpitaux Universitaires de Genève, Geneva, Switzerland*; Martin A. Seule, MD, Andrea Ferrari, MD, Astrid Weyerbrock, MD, Martin Hlavica, MD, Jean-Yves Fournier, MD: *Department of Neurosurgery, Kantonsspital St.Gallen*; Severin Früh, PhD: *Neuropsychological Unit, Department of Neurology, Kantonsspital St.Gallen, Switzerland*; Bawarjan Schatlo, MD: *Department of Neurosurgery, Universitätsmedizin Göttingen, Göttingen, Germany*; Jan-Karl Burkhardt, MD, Martin N. Stienen, MD, Emanuela Keller, MD, Luca Regli, MD, Oliver Bozinov, MD, Nicolai Maldaner, MD, Sina Tok, MD, Marian C. Neidert, MD: *Department of Neurosurgery, Universitätsspital Zürich, Universität Zürich*; Peter Brugger, PhD, Christian Mondadori, PhD: *Neuropsychological Unit, Department of Neurology, Universitätsspital Zürich, Universität Zürich, Switzerland*.

References

- Brouwers HB, Backes D, Kimberly WT, Schwab K, Romero JM, Velthuis BK, Klijn CJ, Ogilvy CS, Regli L, Greenberg SM, Rosand J, Rinkel GJ, Goldstein JN (2013) Computed tomography angiography spot sign does not predict case fatality in aneurysmal subarachnoid hemorrhage with intraparenchymal extension. *Stroke*; *J Cereb Circ* 44:1590–1594
- Brouwers HB, Chang Y, Falcone GJ, Cai X, Ayres AM, Battey TW, Vashkevich A, McNamara KA, Valant V, Schwab K, Orzell SC, Bresette LM, Feske SK, Rost NS, Romero JM, Viswanathan A, Chou SH, Greenberg SM, Rosand J, Goldstein JN (2014) Predicting hematoma expansion after primary intracerebral hemorrhage. *JAMA Neurol* 71:158–164
- Brouwers HB, Greenberg SM (2013) Hematoma expansion following acute intracerebral hemorrhage. *Cerebrovasc Dis* 35:195–201
- Burkhardt JK, Neidert MC, Mohme M, Seifert B, Regli L, Bozinov O (2015) Initial Clinical Status and Spot Sign Are Associated with Intraoperative Aneurysm Rupture in Patients Undergoing Surgical Clipping for Aneurysmal Subarachnoid Hemorrhage. *J Neurol Surg A Cent Eur Neurosurg*
- Del Giudice A, D'Amico D, Sobesky J, Wellwood I (2014) Accuracy of the spot sign on computed tomography angiography as a predictor of haematoma enlargement after acute spontaneous intracerebral haemorrhage: a systematic review. *Cerebrovasc Dis* 37:268–276
- Delgado Almandoz JE, Yoo AJ, Stone MJ, Schaefer PW, Goldstein JN, Rosand J, Oleinik A, Lev MH, Gonzalez RG, Romero JM (2009) Systematic characterization of the computed tomography angiography spot sign in primary intracerebral hemorrhage identifies patients at highest risk for hematoma expansion: the spot sign score. *Stroke*; *J Cereb Circ* 40:2994–3000
- Demchuk AM, Dowlatshahi D, Rodriguez-Luna D, Molina CA, Blas YS, Dzialowski I, Kobayashi A, Boulanger JM, Lum C, Gubituz G, Padma V, Roy J, Kase CS, Kosior J, Bhatia R, Tymchuk S, Subramaniam S, Gladstone DJ, Hill MD, Aviv RI, group PRSICs (2012) Prediction of haematoma growth and outcome in patients with intracerebral haemorrhage using the CT-angiography spot sign (PREDICT): a prospective observational study. *Lancet Neurol* 11:307–314
- Goldstein JN, Fazen LE, Snider R, Schwab K, Greenberg SM, Smith EE, Lev MH, Rosand J (2007) Contrast extravasation on CT angiography predicts hematoma expansion in intracerebral hemorrhage. *Neurology* 68:889–894
- Guresir E, Beck J, Vatter H, Setzer M, Gerlach R, Seifert V, Raabe A (2008) Subarachnoid hemorrhage and intracerebral hematoma: incidence, prognostic factors, and outcome. *Neurosurgery* 63: 1088–1093, discussion 1093–1084
- Hauerberg J, Eskesen V, Rosenorn J (1994) The prognostic significance of intracerebral haematoma as shown on CT scanning after aneurysmal subarachnoid haemorrhage. *Br J Neurosurg* 8:333–339
- Liu X, Rinkel GJ (2011) Aneurysmal and clinical characteristics as risk factors for intracerebral haematoma from aneurysmal rupture. *J Neurol* 258:862–865
- Pegoli M, Mandrekar J, Rabinstein AA, Lanzino G (2015) Predictors of excellent functional outcome in aneurysmal subarachnoid hemorrhage. *J Neurosurg* 122:414–418
- Rosengart AJ, Schultheiss KE, Tolentino J, Macdonald RL (2007) Prognostic factors for outcome in patients with aneurysmal subarachnoid hemorrhage. *Stroke*; *J Cereb Circ* 38:2315–2321
- Schatlo B, Fung C, Fathi AR, Sailer M, Winkler K, Daniel RT, Bijlenga P, Ahlborn P, Seule M, Zumofen D, Reinert M, Woernle C, Stienen M, Levivier M, Hildebrandt G, Mariani L, Bernays R, Fandino J, Raabe A, Keller E, Schaller K (2012) Introducing a nationwide registry: the Swiss study on aneurysmal subarachnoid

- haemorrhage (Swiss SOS). *Acta Neurochir* 154:2173–2178, discussion 2178
15. Suarez JI, Tarr RW, Selman WR (2006) Aneurysmal subarachnoid hemorrhage. *N Engl J Med* 354:387–396
 16. van Gijn J, Kerr RS, Rinkel GJ (2007) Subarachnoid haemorrhage. *Lancet* 369:306–318
 17. Wada R, Aviv RI, Fox AJ, Sahlas DJ, Gladstone DJ, Tomlinson G, Symons SP (2007) CT angiography “spot sign” predicts hematoma expansion in acute intracerebral hemorrhage. *Stroke; J Cereb Circ* 38:1257–1262
 18. Wilson DA, Nakaji P, Abla AA, Uschold TD, Fusco DJ, Oppenlander ME, Albuquerque FC, McDougall CG, Zabramski JM, Spetzler RF (2012) A simple and quantitative method to predict symptomatic vasospasm after subarachnoid hemorrhage based on computed tomography: beyond the Fisher scale. *Neurosurgery* 71:869–875